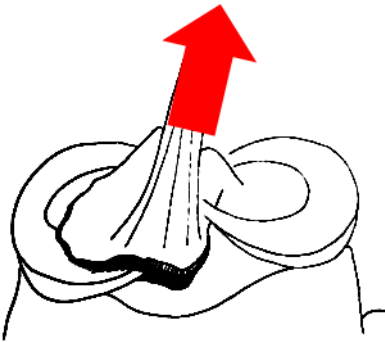


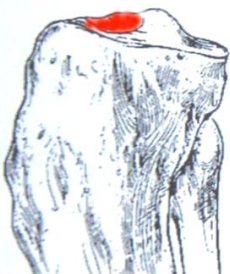Fracture de l'éminence intercondylienne du tibia



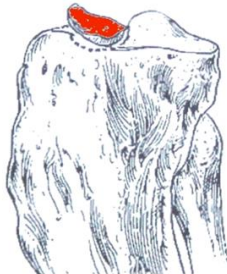Meyers MH, McKeever FM. Fracture of the intercondylar eminence of the tibia. J Bone Joint Surg Am. 1959;41-a(2):209-222.

Meyers & McKeevers

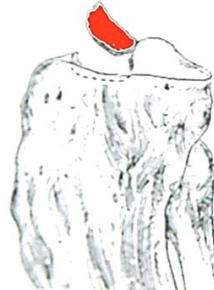TYPE I



TYPE II



TYPE IIIB



TYPE IV

